

# Nail Bed Injuries

## What is involved?

Injuries to the nail are often associated with damage to other structures that are in the same location. These include fractures of the bone (distal phalanx), and/or cuts of the nailbed, fingertip skin (pulp), tendons that straighten or bend the fingertip, and nerve endings.

## What causes them?

Many result from crush injuries after getting the fingertip caught in a door. Any type of pinching, crushing, or sharp cut to the fingertip may result in injury to the nail bed.

## Presentation

Simple crushes of the fingertip may result in a very painful collection of blood (hematoma) under the nail. More severe injuries can result in cracking of the nail into pieces, or tearing off of pieces of the nail and/or fingertip, and possible injuries to the adjacent structures.

## Diagnosis

An accurate history of the cause of the injury should be obtained. X-rays are recommended to look for associated fractures that may require treatment. The full extent of the injury may not be evident until adequate anesthesia (usually local) is given and the nail is examined with magnification. Other medical conditions that may affect healing should be discussed with your physician.

## Treatment

Restoring the normal anatomy of the nail and surrounding structures is the goal of treatment. Simple hematomas are drained by making a small hole in the nail in order to relieve the pressure and provide pain relief. Straightforward cuts are repaired to put the parts back where they belong. Repairing the nail bed to which the fragments of bone are attached usually restores alignment of many fractures of the fingertip. Larger fragments of bone may need to be pinned or require splinting to heal the fracture. Missing areas of nail bed can be grafted from the same finger or from other digits. Tendon injury may require splinting or pinning. Local flaps of skin may be used to replace missing skin, or the open area of skin may be allowed to just heal on its own, or covered with a skin graft.

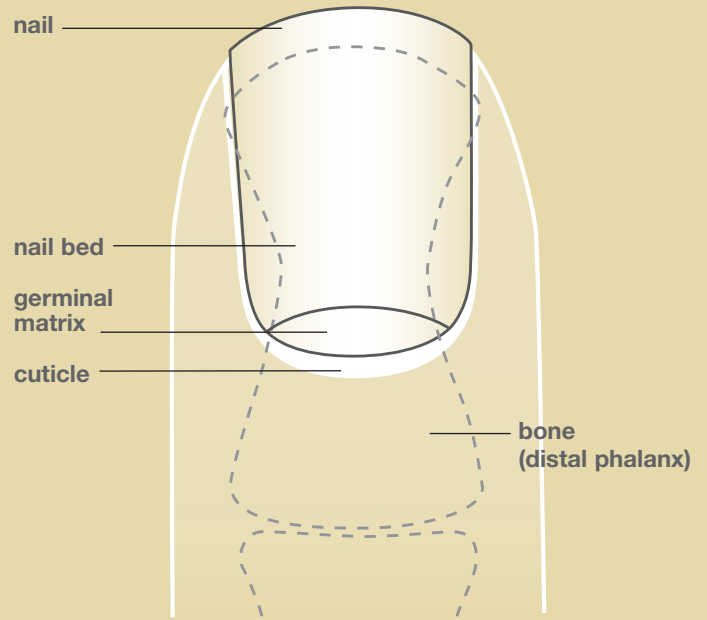
## Prognosis

The final appearance and function of the nail and surrounding structures depends on the ability to restore the normal anatomy. If the injury is sharp and can be repaired, a normal nail is likely. If there is more severe crushing of the nail bed, then there is a greater likelihood of nail bed scarring and subsequent deformity of the nail. If the germinal matrix (crescent-shaped zone at the base of the nail bed from which the nail grows) is injured, there will likely be a deformity of the nail as it grows. The function of the fingertip also depends on the extent of injury to structures other than the nail. It normally takes 3-6 months for the nail to grow from the cuticle to the tip of the finger.

## Surgical Reconstruction

Loss of part or all of the nail bed can be reconstructed with grafts from other digits. Grafts may be taken from the nail bed of a toe to prevent further injury or deformity of the fingers. The most common graft is a split-thickness graft to reconstruct missing nail bed.

**Figure 1:** The anatomy of the nail bed and surrounding structures.



**Figure 2:** The anatomy of the nail bed and surrounding structures from a lateral view.

